

Aesthetic Surgery Journal

<http://aes.sagepub.com/>

A Prospective Study of 708 Form-Stable Silicone Gel Breast Implants

W. Grant Stevens, Elliot M. Hirsch, Marissa J. Tenenbaum and Maria Acevedo

Aesthetic Surgery Journal 2010 30: 693

DOI: 10.1177/1090820X10381880

The online version of this article can be found at:

<http://aes.sagepub.com/content/30/5/693>

Published by:



<http://www.sagepublications.com>

On behalf of:



[American Society for Aesthetic Plastic Surgery](http://www.asap.org)

Additional services and information for *Aesthetic Surgery Journal* can be found at:

Email Alerts: <http://aes.sagepub.com/cgi/alerts>

Subscriptions: <http://aes.sagepub.com/subscriptions>

Reprints: <http://www.sagepub.com/journalsReprints.nav>

Permissions: <http://www.sagepub.com/journalsPermissions.nav>

A Prospective Study of 708 Form-Stable Silicone Gel Breast Implants

W. Grant Stevens, MD, FACS; Elliot M. Hirsch, MD;
Marissa J. Tenenbaum, MD; and Maria Acevedo

Aesthetic Surgery Journal
30(5) 693–701
© 2010 The American Society for
Aesthetic Plastic Surgery, Inc.
Reprints and permission:
[http://www.sagepub.com/
journalsPermissions.nav](http://www.sagepub.com/journalsPermissions.nav)
DOI: 10.1177/1090820X10381880
www.aestheticsurgeryjournal.com



Abstract

Background: Form-stable silicone gel breast implants represent the fifth generation of silicone gel augmentation devices. Additional crosslinking between the silicone molecules allows these implants to retain their shape, especially in the vertical position.

Objective: The authors evaluate the efficacy of Silimed form-stable silicone gel breast implants.

Methods: A total of 355 patients (708 implants) were enrolled prospectively over a 60-month period. Data were collected on patient demographics, implant factors, complications, and revisions. Chi-square analysis and Fisher's exact test were implemented to compare groups with respect to differences in complication and revision rates.

Results: The overall tissue-related complication rate was 8.2% per patient, or 4.1% per breast. The overall implant-related cosmetic complication rate was 2.5% per patient, or 1.3% per implant. The overall implant-related complication rate, which was represented by the capsular contracture (CC) rate, was 1.4% per patient and 0.7% per implant. There were no complications in any of the reconstruction patients. There were no deep vein thromboses, pulmonary emboli, myocardial infarctions, or deaths among the patients in this study. In addition, there were no instances of flap necrosis, hematoma, or loss of implant integrity. The overall complication rate was 9.6% per patient, or 4.8% per implant. The overall tissue-related revision rate was 5.4% per patient, with the most common tissue-related reason for revision being unacceptable scarring. The overall implant-related cosmetic revision rate was 7.6% per patient, with the most common reason for revision in this category being size change. The overall implant-related revision rate was 1.1% per patient and was solely due to CC.

Conclusions: This study demonstrates that form-stable silicone gel breast implants are safe and have a complication profile similar to other models of silicone breast implants, with a lower CC rate and a decreased incidence of wrinkling compared to fourth-generation silicone gel implants (as well as other published studies of fifth-generation implants).

Keywords

breast augmentation, silicone gel, form-stable implants, crosslinking, capsular contracture

Accepted for publication July 27, 2010.

EDITOR'S NOTE: In this article, the author discusses the placement of breast implants through a transaxillary incision. Currently, both US manufacturers have issued warnings regarding the risks of implant damage with remote incision sites. Patients should be informed of these warnings during preoperative planning.

Form-stable silicone gel (or "gummy bear") implants represent the fifth generation of silicone gel devices available for breast augmentation. As compared to fourth-generation silicone gel breast implants, the presence of additional crosslinking between the silicone molecules has allowed these implants to better retain their shape, especially in the vertical position.¹ Consequently, these implants have several purported advantages over fourth-generation

silicone or saline breast implants. The fact that these implants retain their shape in the upright position allows for added volume in the upper pole of the breast and also helps to reduce the incidence of folding and rippling. By decreasing rippling, wear and tear on the implant shell

Dr. Grant is a plastic surgeon in private practice in Marina del Rey, California. Dr. Hirsch is a resident in the Division of Plastic and Reconstructive Surgery, Northwestern University Feinberg School of Medicine, Chicago, Illinois. Dr. Tenenbaum is an assistant professor in the Division of Plastic and Reconstructive Surgery, Washington University School of Medicine, St. Louis, Missouri. Ms. Acevedo is a nurse in private practice in Marina del Rey, California.

Corresponding Author:

Dr. W. Grant Stevens, 4644 Lincoln Boulevard, Suite 552, Marina del Rey, CA 90292.

E-mail: DrStevens@hotmail.com



Figure 1. The Silimed textured, round, high-profile silicone cohesive gel breast implant. Photo courtesy of Sientra, Inc.

should also be decreased, which should theoretically decrease the rupture rate. If the implant shell does in fact lose integrity, the cohesive nature of the silicone gel can limit silicone leakage.

Development of these implants began in the early 1990s, almost concurrently with fourth-generation implants. Although they are available to the public in Europe, they are currently only available in the United States for patients who are participating in approved clinical trials. As such, there is a lack of information in the literature about their efficacy. In this study, the authors discuss the experience of the senior author (WGS) with 708 Silimed (Sientra, Inc., Santa Barbara, California) textured form-stable silicone cohesive gel breast implants (Model 20621; Figure 1) over a 60-month period.

METHODS

A total of 355 patients were enrolled prospectively as part of the Silimed form-stable silicone cohesive gel breast implant study. Those 355 patients received 708 breast implants during a 60-month period, 98% of which were high-profile textured round implants.

To be included in the study, patients were required to be female, have adequate tissue to cover the implant, and be willing to follow the study requirements (including completing an informed consent document and agreeing to postoperative follow-up visits). Primary augmentation patients had to be 18 years of age or older. For primary reconstruction patients, no age limit was applied. The same age criteria applied to patients who were seeking a revision. Each patient's candidacy for the required procedure was determined as follows:

Augmentation. Patients who demonstrated severe ptosis, general breast enlargement, and/or asymmetry.

Reconstruction. Patients who presented with (1) postmastectomy or postlumpectomy as a result of cancer or other diseases; (2) posttrauma with total or partial removal of breast(s) resulting in significant deformity (for any reason); (3) congenital deformities or acquired discrepancy in breast size resulting in significant physical deformity, including but not limited to pectus excavatum, pectus carinatum, scoliosis, Poland's syndrome, and tuberous breast; or (4) contralateral augmentation mammoplasty as a result of the affected breast requiring surgery when medically indicated to provide symmetry.

Revision. Patients who desired replacement of an existing breast implant for medical or surgical reasons.

A patient was excluded if she:

1. had inadequate or unsustainable tissue (eg, due to radiation damage, ulceration, compromised vascularity, history of compromised wound healing);
2. showed evidence of advanced fibrocystic disease considered to be premalignant upon mastectomy;
3. had an active infection at the time of surgery;
4. was pregnant or lactating;
5. had a medical condition (obesity, diabetes, autoimmune disease, chronic lung disease, or severe cardiovascular disease) that might, in the opinion of the investigator, result in unduly high surgical risk and/or significant postoperative complications;
6. was taking drugs (prescription or otherwise, including those that interfere with blood clotting) that might result in a high-risk profile and/or significant postoperative complications;
7. demonstrated psychological characteristics that correlated with unrealistic or unreasonable desires, or a lack of understanding of the risks involved with the surgical procedure;
8. had an connective tissue/autoimmune disorder, such as systemic lupus erythematosus, discoid lupus, or scleroderma;
9. had existing carcinoma of the breast without accompanying mastectomy; or
10. was unable to undergo a magnetic resonance imaging (MRI) scan because of implanted metal device, claustrophobia, or other conditions.

Operative Technique

All breast implant procedures were performed by the senior surgeon (WGS) at the same private practice outpatient ambulatory surgery center. All patients were placed under general anesthesia, preoperative intravenous antibiotics were given in all cases, and a "minimal touch" technique was employed in all cases. Prior to implant placement, the surgical pockets were irrigated with a dilute betadine solution. Implants were placed in either submuscular or subglandular pockets and were inserted through periareolar, inframammary fold, mastopexy, or mastectomy scar incisions. All incisions were closed in layers.

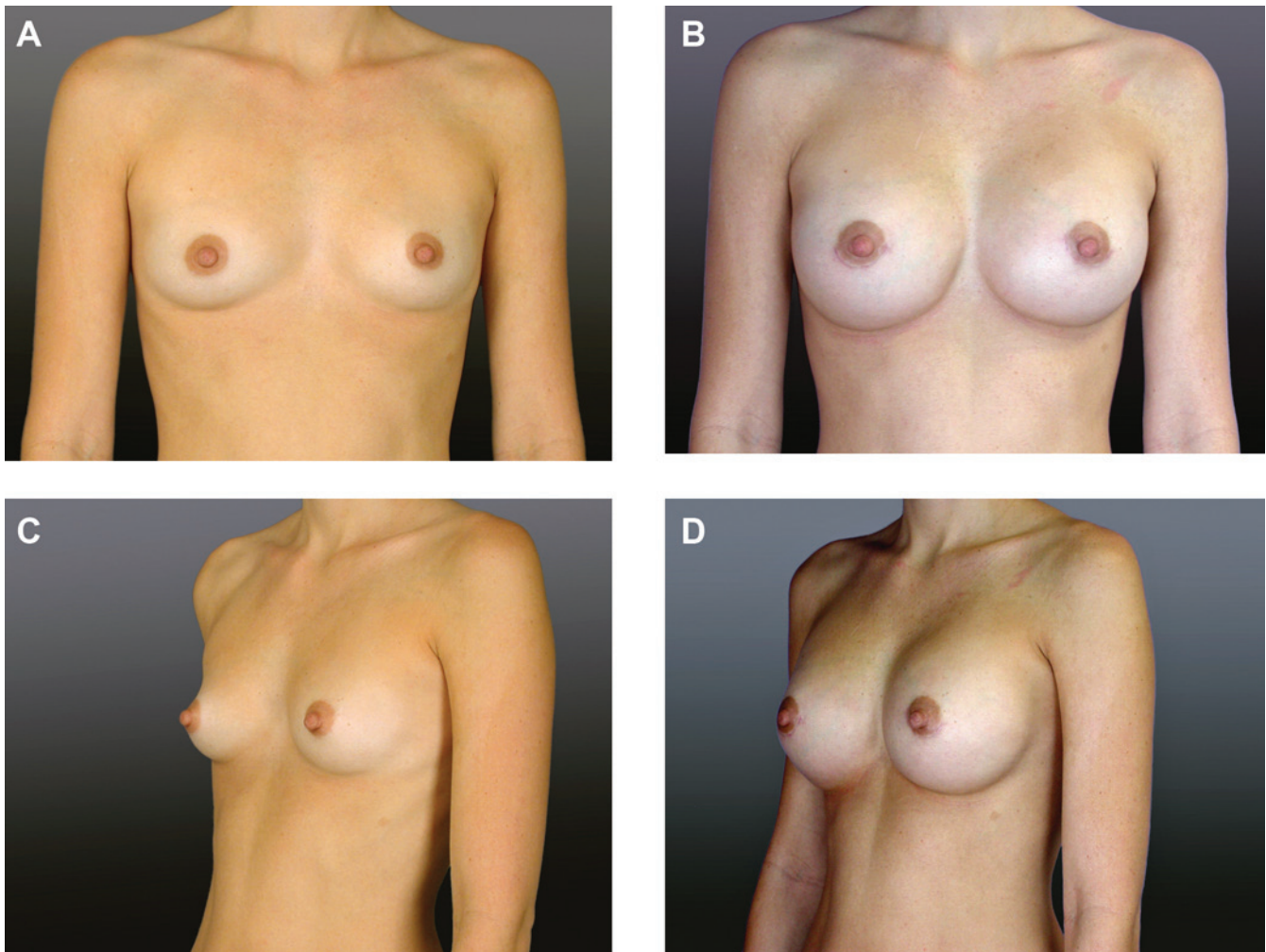


Figure 2. (A, C) This 30-year-old woman presented for primary breast augmentation. She was 5'4", 115 pounds, and had a cup size of 34A prior to treatment. (B, D) Three months after placement of 280 cc Silimed form-stable silicone cohesive gel implants through a periareolar incision in a submuscular plane. The patient's postoperative cup size was 34C.

The preliminary clinical results for three patients (two primary augmentation and one primary augmentation mastopexy) are shown in Figures 2 to 4.

Postoperative Care

Postoperatively, each patient was placed in a supportive bra and advised to avoid strenuous exercise for two weeks. They were also given three to five days of oral antibiotics. No surgical drains were placed in any case.

All patients were seen on the first postoperative day and again during the first postoperative week. Further follow-up occurred between three and six months, at one year, and each year thereafter or as necessary.

Data Analysis

Chi-square analysis and Fisher's exact test were applied to compare the groups (augmentation, reconstruction, and

revision) with respect to differences in complication and revision rates. Data analysis was based on "intention to treat" procedures; data from patients who were lost to follow-up were included in the final analysis. Of note, the statistical outcomes of this study did not change when these data were included or excluded from the analysis.

RESULTS

Mean follow-up for the 355 patients was 28 months. Six patients were lost to follow-up and three patients were electively explanted. During the study, information was collected on patient demographics, implant factors, and complications and revisions. The grades of capsular contracture (CC) were determined by the senior surgeon (WGS).

The average patient age in this study was 38 years (range, 18-65). Implant sizes ranged from 135 to 1000 cc, with a mean of 394 cc. Twenty-one patients were smokers. The indications for implantation are shown in Figure 5.

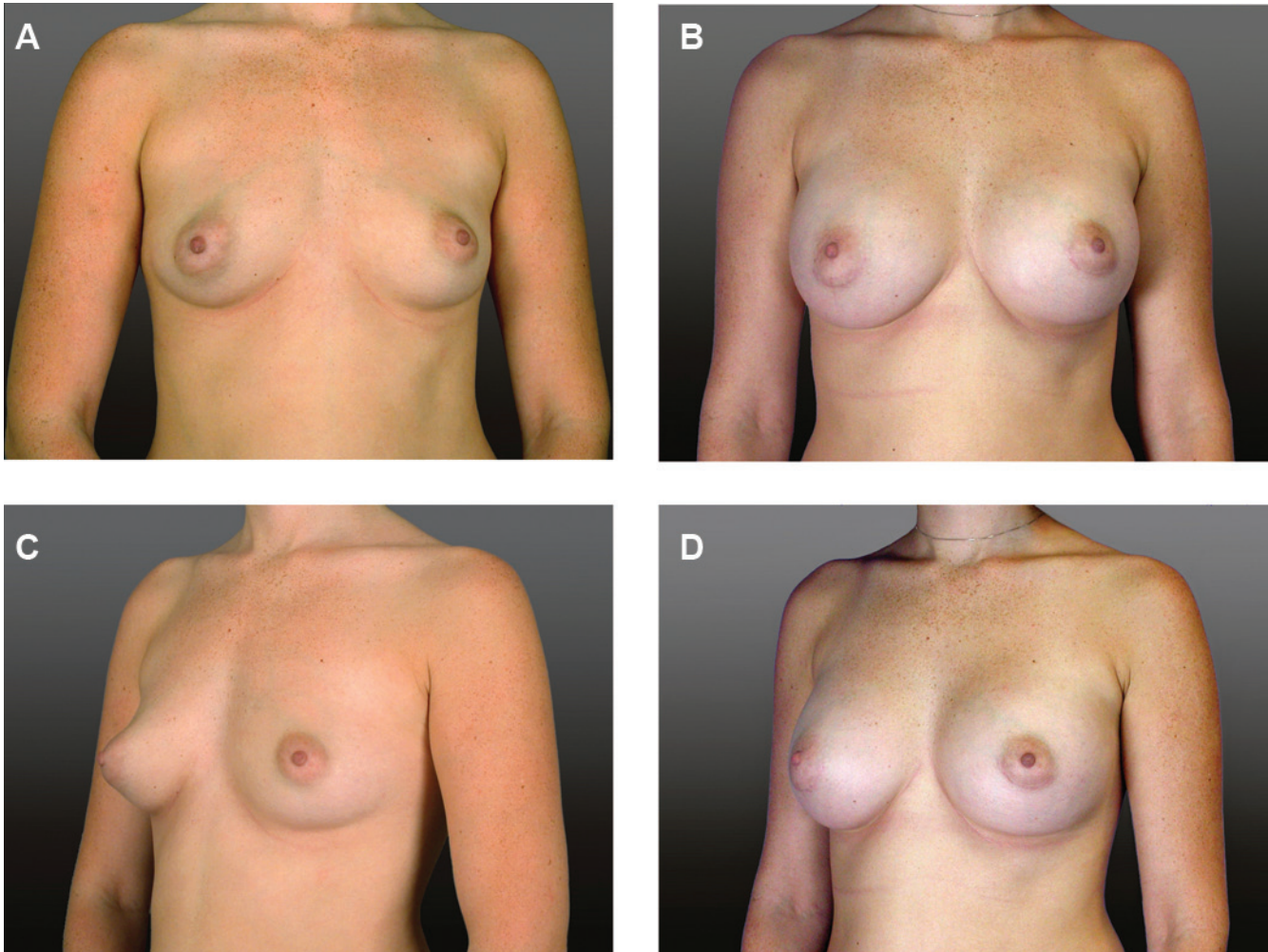


Figure 3. (A, C) This 23-year-old woman presented for primary breast augmentation. She was 5'7" and 130 pounds. (B, D) Three months after placement of 385 cc Silimed form-stable silicone cohesive gel implants through a periareolar incision in a submuscular plane.

Among primary augmentation procedures, the largest percentage of implants was placed submuscularly (90%) and through a periareolar incision (78%). The full distribution of incision and placement for both primary and secondary augmentation procedures is shown in Table 1.

Based on a recent editorial,² to clearly delineate their etiologies, complications were divided into three groups: tissue-related (defined as complications that may occur following any breast operation), implant-related cosmetic (defined as complications that are primarily cosmetic in nature and are related to the presence of the implant, such as wrinkling/rippling), and implant-related (defined as complications that are specific to the implant, such as CC or deflation). Tables 2, 3, and 4 illustrate the data regarding each of these complication rates for primary augmentation, secondary augmentation, primary mastopexy augmentation, and secondary mastopexy augmentation.

The overall tissue-related complication rate was 8.2% per patient, or 4.1% per breast. The overall implant-related cosmetic complication rate was 2.5% per patient, or 1.3% per implant. The overall implant-related complication rate, which was represented by the CC rate, was 1.4% per patient and 0.7% per implant. There were no complications in any of the reconstruction patients. There were no deep vein thromboses, pulmonary emboli, myocardial infarctions, or deaths among the patients in this study. In addition, there were no instances of flap necrosis, hematoma, or loss of implant integrity. The overall complication rate was 9.6% per patient, or 4.8% per implant.

Based on the previously-mentioned editorial,² revisions were also divided into three groups: tissue related (defined as revisions after implant surgery that may occur following any breast operation), implant-related cosmetic (defined as elective revisions or interventions following

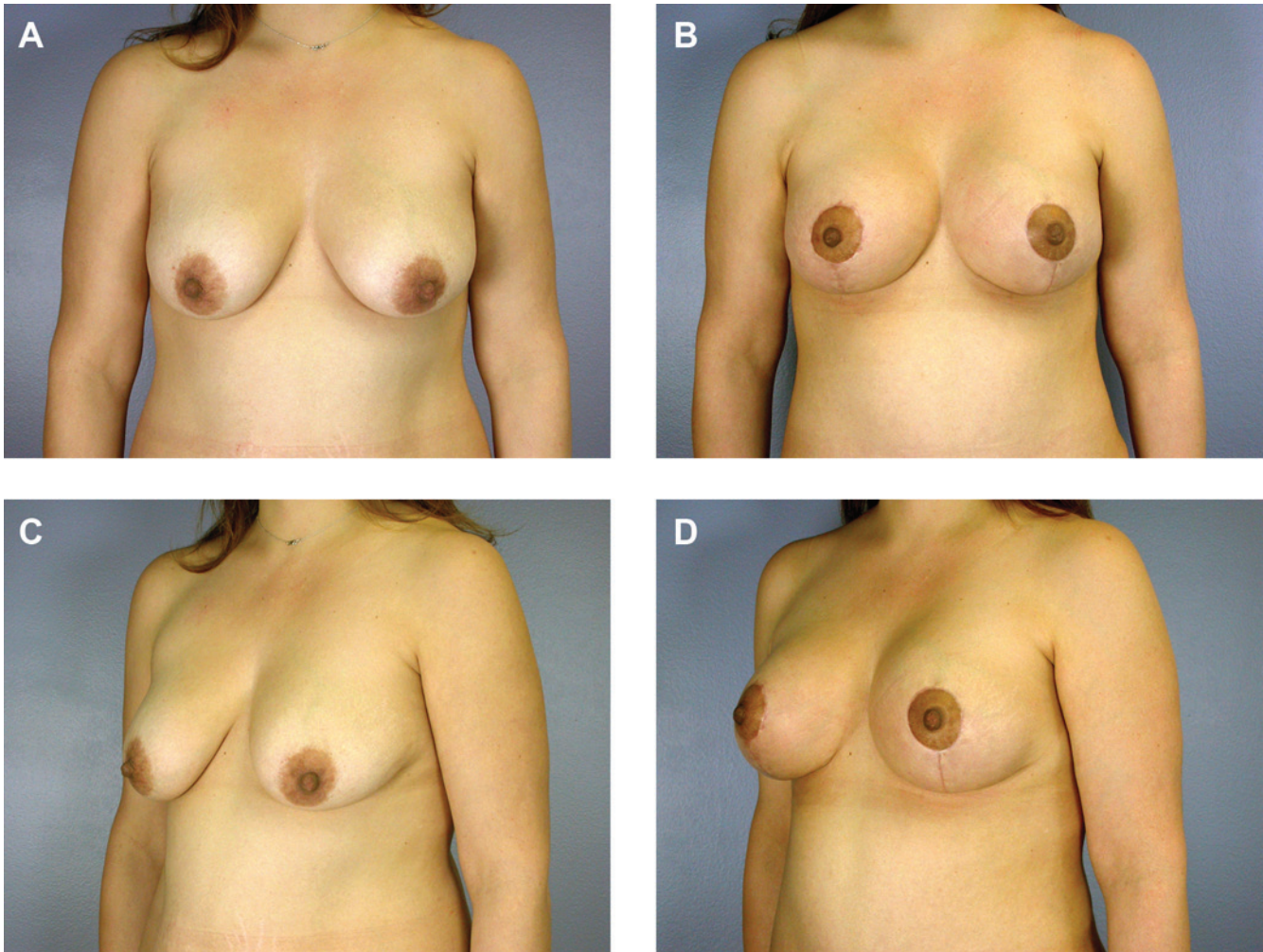


Figure 4. (A, C) This 31-year-old woman presented for mastopexy augmentation. She was 5'5" and weighed 150 pounds. She had previously nursed two children. (B, D) Three months after placement of 175 cc Silimed form-stable silicone cohesive gel implants.

Table 1. Distribution of Incision Location and Implant Placement

Procedure	Periareolar Incision, %	Inframammary Fold Incision, %	Submuscular Placement, %	Subglandular Placement, %
Primary augmentation	78	22	90	10
Secondary augmentation	75	25	80	20

implant surgery that are at the patient's discretion and are more cosmetic in nature), and implant-related (defined as revisions for significant cosmetic problems directly related to the implant). These revisions are illustrated in Tables 5, 6, and 7. The overall tissue-related revision rate was 5.4% per patient, or 2.7% per implant, with the most common tissue-related reason for revision being unacceptable scarring. The overall implant-related cosmetic revision rate

was 7.6% per patient, or 3.8% per implant, with the most common reason for revision in this category being size changes. The overall implant-related revision rate was 1.1% per patient, or 0.6% per implant, and was solely due to CC. The overall revision rate was 9.0%, or 4.5% per implant.

No statistically-significant differences were found with respect to complication or revision rates when

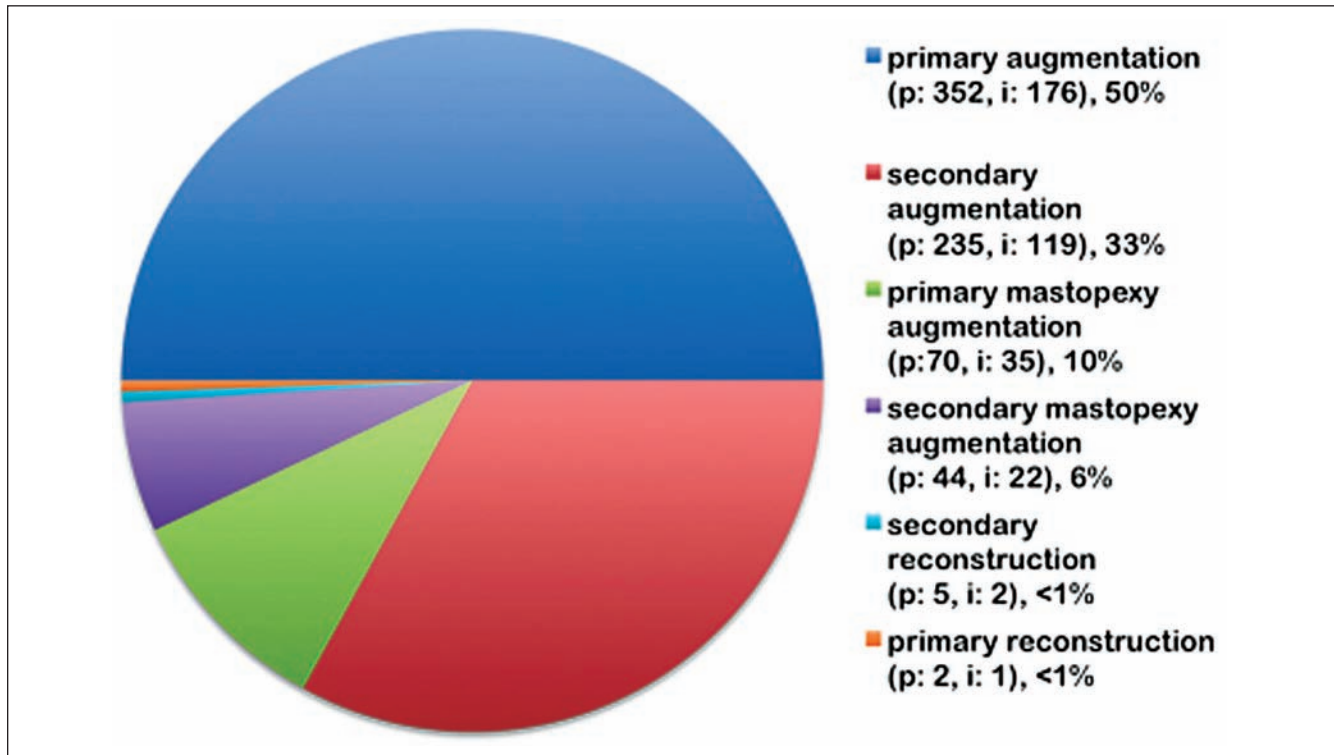


Figure 5. Indications for implantation. p = patients, i = implants. % represents percent of total procedures.

Table 2. Tissue-Related Complications

	Primary Augmentation	Secondary Augmentation	Primary Mastopexy Augmentation	Secondary Mastopexy Augmentation	Total
Scar related	3	2	6	4	15
Seroma	5	1	1	0	7
Infection	2	1	0	2	5
Galactorrhea	0	0	2	0	2
Total	10	4	9	6	29
% per patient	5.7	3.4	25.7	27.3	8.2
% per breast	2	1.7	12.9	13.6	4.1

patient groups were examined based on age, smoking status, or implant size ($P > .05$ in all cases). In addition, when the complication and revision rates for primary and secondary augmentation groups were independently compared based on incision type or implant placement, no statistically-significant differences were found ($P > .05$ in all cases). Finally, no statistically-significant differences in complication or revision rates were found between primary and secondary procedures ($P > .05$ in all cases).

DISCUSSION

As outlined previously, form-stable silicone gel breast implants represent the fifth generation of silicone breast

implants under investigation. We found no statistically-significant associations between complications/revisions and the demographic or implant-related factors that were examined. These results are comparable to a recent study by our group that examined the outcomes of our experience with fourth-generation silicone gel breast implants (Mentor MemoryGel) and found a complication rate of 5.5% per implant and a revision rate of 6.8% per implant, at an average of 34 months follow-up.³ Of note, the CC rate among fifth-generation implants in this study (0.7% per implant) was lower than the rate among fourth-generation implants (2.6% per implant) in our prior study. The extremely low CC rate is consistent with recently published studies of other form-stable silicone cohesive gel breast implants (0%-5.6% per patient at average follow-up times of 21-72 months).^{1,4-7} The etiology of this low CC

Table 3. Implant-Related Cosmetic Complications

	Primary Augmentation	Secondary Augmentation	Primary Mastopexy Augmentation	Secondary Mastopexy Augmentation	Total
Upper pole fullness	2	0	1	0	3
Implant malposition	1	0	1	0	2
Wrinkling	2	0	0	0	2
Ptosis	0	2	0	0	2
Total	5	2	2	0	9
% per patient	2.9	1.7	5.7	0	2.5
% per implant	1.4	0.9	2.9	0	1.3

Table 4. Implant-Related Complications

	Primary Augmentation	Secondary Augmentation	Primary Mastopexy Augmentation	Secondary Mastopexy Augmentation	Total
Capsular contracture	2 ^a	2 ^a	1 ^a	0	5
% per patient	1.2	1.7	2.9	0	1.4
% per implant	0.6	0.8	1.4	0	0.7

^aPrimary augmentation contractures both occurred at three years; secondary augmentation contractures occurred at three months and one year, respectively; primary augmentation mastopexy contracture occurred at 3.5 months.

Table 5. Tissue-Related Revisions

Tissue-Related Revisions	Primary Augmentation	Secondary Augmentation	Primary Mastopexy Augmentation	Secondary Mastopexy Augmentation	Total
Unacceptable scarring	1	1	6	4	12
Seroma	1	1	1	0	3
Infection	1	0	0	2	3
Wound exploration	1	0	0	0	1
Total	4	2	7	6	19
% per patient	2.3	1.7	20	27.3	5.4
% per implant	1.2	0.9	10	13.6	2.7

Table 6. Implant-Related Cosmetic Revisions

Implant-Related Cosmetic Revisions	Primary Augmentation	Secondary Augmentation	Primary Mastopexy Augmentation	Secondary Mastopexy Augmentation	Total
Size changes	8	6	5	4	23 ^a
Implant malposition	1	0	1	0	2
Ptosis	0	2	0	0	2
Total	9	8	6	4	27
% per patient	5.2	6.8	17.1	18.2	7.6
% per implant	2.6	3.4	8.6	9.0	3.8

^aFifteen implant size changes were for larger implants; eight were for smaller.

Table 7. Implant-Related Revisions

Implant-Related Revisions	Primary Augmentation	Secondary Augmentation	Primary Mastopexy Augmentation	Secondary Mastopexy Augmentation	Total
Capsular contracture	1	2	1	0	4
% per patient	0.6	1.7	2.9	0	1.1
% per implant	0.3	0.9	1.4	0	0.6

rate is unclear but is likely attributable to multiple factors, including increased resistive forces from the form-stable silicone gel or decreased microleak of silicone from the internal implant.⁴⁻⁵ Additionally, the prevalence of submuscular implant placement may contribute to the observed rates in this study, although a larger sample size would be needed to examine the effect of subglandular versus submuscular implant placement on the rate of CC with form-stable devices.

Another potential factor in the low CC rate observed in the patients in this study is the application of dilute betadine solution in pocket irrigation prior to implant insertion. Although early studies postulated a theoretical risk of deflation with betadine,^{8,9} more recent research (as well as our own experience) indicates that this is not the case.¹⁰ With studies confirming the protective effect against capsular contracture in vitro,¹¹ this factor may be a significant contributor to the low capsular contracture rate seen in this study.

The incidence of implant wrinkling or visible rippling was also very low (less than 1% of patients) in this study. This finding is similar to other studies of form-stable implants⁷ and is significantly lower than rates observed in studies of saline devices.¹² The authors' own experience also supports these data. Given that patients with lower body mass index (BMI) and less native breast tissue volume often have a higher incidence of saline breast implant wrinkling, form-stable silicone gel implants present a viable alternative for these cases.

In this study, the mastopexy augmentation procedures had noticeably higher complication and revision rates than augmentation alone. However, this is an expected finding; the complication and revision rates of these procedures in this study are similar to previously published complication and revision rates of one-stage mastopexy augmentation procedures by this group, which found overall complication and revision rates of approximately 20% and 15%, respectively.^{13,14} In addition, when scar-related complications are excluded from the analysis, the complication and revision rates from the combined procedures approach those of augmentation alone.

More than 75% of implants placed in primary or secondary augmentation procedures were inserted through periareolar incisions. This is in contrast to previous studies of form-stable silicone cohesive gel breast implants, which postulated that these implants should be placed through larger incisions in the inframammary fold to avoid an internal gel microfracture and to obtain better control of

implant position.^{1,4,5,7} In these studies, more than 75% of implants in augmentation procedures were placed through inframammary fold incisions.^{1,4,5,7} Although it is possible that internal microfracture of the silicone cohesive gel may occur with periareolar placement, it does not appear to affect outcomes, as there was no statistically-significant difference in complication or revision rates when augmentation outcomes were compared based on incision location ($P > .05$).

When selecting the incision site with silicone cohesive gel breast implants, a variety of factors must be considered. Patient preference for the inframammary fold or periareolar incision should be taken into account, bearing in mind that the periareolar incision is not suitable for all patients. An incision of 3.5 to 4.5 cm (depending on the implant volume) is needed to insert these implants and the authors believe that the incision should remain inferior to the 3 o'clock to 9 o'clock position, preferably between 4 o'clock and 8 o'clock. Given the required incision size, each patient must have a minimum areolar diameter of approximately 3.5 cm. Patients who desire a periareolar incision and have small areolas may be required to choose either a smaller implant or a different incision. Ultimately, careful preoperative planning that balances patient preference with biometric properties is paramount.

As a side note, critics of these implants have postulated that form-stable cohesive gel breast implants are firmer to the touch than other silicone implants, but this has not been the case in our experience. In this study, no patient complained of breast firmness or hardness on follow-up.

CONCLUSIONS

This study demonstrates the safety and efficacy of Silimed form-stable silicone gel breast implants. With respect to their complication profile, in the authors' experience, these implants have complication and revision rates similar to fourth-generation silicone breast implants with lower capsular contracture rates. Placement of these implants in secondary procedures did not result in statistically significant increases in complication or revision rates. Finally, these implants can be safely and accurately inserted through periareolar incisions, provided that careful preoperative planning is undertaken prior to surgery. Thus, form-stable silicone cohesive gel breast implants should be considered a viable alternative to fourth-generation silicone gel breast implants.

Disclosures

Dr. Stevens has been compensated for his participation as an investigator in the Silimed Form-stable Silicone Cohesive Gel Breast Implant Study.

Funding

The authors received no financial support for the research and/or authorship of this article.

REFERENCES

1. Brown MH, Shenker R, Silver SA. Cohesive silicone gel breast implants in aesthetic and reconstructive breast surgery. *Plast Reconstr Surg* 2005;116:768-779.
2. Spear SL. Redefining reoperations. *Plast Reconstr Surg* 2008;122:1279-1280.
3. Stevens WG, Pacella SJ, Gear AL, McWhorter C, Stoker DA. Clinical experience with a fourth generation textured silicone gel breast implant: a review of 1012 Mentor MemoryGel breast implants. *Aesthetic Surg J* 2008;28:642-647.
4. Heden P, Jernbeck J, Hober M. Breast augmentation with anatomical cohesive gel implants: the world's largest current experience. *Clin Plast Surg* 2001;28:531-552.
5. Heden P, Bone B, Murphy DK, et al. Style 410 Cohesive silicone breast implants: safety and effectiveness at 5 to 9 years after implantation. *Plast Reconstr Surg* 2006;118:1281.
6. Fruhstorfer BH, Hodgson EL, Malata CM. Early experience with an anatomical soft cohesive silicone gel prosthesis in cosmetic and reconstructive breast implant surgery. *Ann Plast Surg* 2004;53:536-542.
7. Bengston BP, Van Natta BW, Murphy DK, Slicton A, Maxwell GP. Style 410 highly cohesive silicone breast implant core study results at 3 years. *Plast Reconstr Surg* 2007;120(suppl 1):40S.
8. Burkhardt BR, Dempsey PD, Schnur PL, Tofield JJ. Capsular contracture: a prospective study of the effect of local antibacterial agents. *Plast Reconstr Surg* 1986;77:919-932.
9. Burkhardt BR, Demas CP. The effect of Siltex texturing and povidone-iodine irrigation on capsular contracture around saline inflatable breast implants. *Plast Reconstr Surg* 1994;93:123-128; discussion 129-130.
10. Wiener TC. The role of betadine irrigation in breast augmentation. *Plast Reconstr Surg* 2007;119:12-15; discussion 16-17.
11. Zambacos GJ, Nguyen D, Morris RJ. Effect of povidone iodine on silicone gel breast implants in vitro: implications for clinical practice. *Plast Reconstr Surg* 2004;114:706-710; discussion 711-712.
12. Al-Sabounchi S, De Mey AM, Eder H. Textured saline-filled breast implants for augmentation mammoplasty: does overfilling prevent deflation? A long-term follow-up. *Plast Reconstr Surg* 2006;118:215-222.
13. Stevens WG, Freeman ME, Stoker DA, Quardt SM, Cohen R, Hirsch EM. One-stage mastopexy with breast augmentation: a review of 321 patients. *Plast Reconstr Surg* 2007;120:1674-1679.
14. Stevens WG, Spring MA, Stoker DA, et al. A review of 100 consecutive secondary augmentation/mastopexies. *Aesthetic Surg J* 2007;27:485-492.