

Outpatient Reduction Mammoplasty: An Eleven-Year Experience

*W. Grant Stevens, MD; Andrew J. L. Gear, MD; David A. Stoker, MD;
Elliot M. Hirsch, MD; Robert Cohen, MD; Michelle Spring, MD; Steve D. Vath, MD;
Steve A. Schantz, MD; and Robert T. Heck, MD*

BACKGROUND: In the last 15 years, reduction mammoplasty has been increasingly performed on an outpatient basis. Despite this evolution, few outcome studies have been published regarding outpatient breast reduction surgery.

OBJECTIVE: The authors documented clinical outcomes of reduction mammoplasty performed in an outpatient setting over an 11-year period and compared these results with published normative values in the plastic surgery literature.

METHODS: A retrospective review was undertaken of 884 reduction mammoplasties in 444 patients at a single outpatient surgical center performed by the senior author (W.G.S.) from 1995 through 2006. In all cases, a laser-assisted, inferior pedicle, Wise pattern, reduction mammoplasty was performed. In addition to demographic and surgical data, complication frequency and type were recorded. Complication data were further stratified into minor and major categories. Potential minor complications included seroma, hematoma, soft tissue infection, dog-ears requiring revision, and small incisional breakdowns or delayed healing of less than 2 cm. Potential major complications included large incisional breakdowns or delayed healing of greater than 2 cm, nipple/areolar necrosis, need for blood transfusion, deep vein thrombosis, pulmonary embolus, myocardial infarction, and death.

RESULTS: The mean patient age was 38 years (range, 16 to 73 years). Mean body-mass index was 27 (range 17 to 47). The reported preoperative brassiere cup sizes ranged from a 34 C to a 38 K, with a DD being the most common size. The mean preoperative sternal notch-to-nipple distance was 29 cm (range 22 to 54 cm). Forty patients smoked (9%). Mean clinical follow-up was 13 months. Mean total resection weight of breast tissue was 1228 g (range 100 to 5295 g). Mean operative time for reduction mammoplasty was 115 minutes (range 50 to 195 minutes). Nineteen percent of patients underwent multiple procedures, including abdominoplasty, lipoplasty, and facial procedures, with a mean operative time of 132 minutes (range 75 to 345 minutes). The overall complication rate was 14%, with 70 minor complications occurring in 62 patients. Specific minor complications included one seroma, four hematomas, eight soft tissue infections, two of which required a short course of intravenous antibiotics, one patient with dog-ears requiring surgical revision, and 56 small incisional wound breakdowns (<2 cm). The small incisional breakdowns, which represented the largest group of complications, were further subdivided into 44 minor T-zone wounds, 3 nipple-areolar complex wounds, and 9 wounds of the vertical and horizontal incisions. Three major complications (0.67%) were recorded. Two patients had development of partial nipple/areolar necrosis. A third patient required anticoagulation for a pulmonary embolus diagnosed 10 days after surgery. Statistical analysis of the complication data revealed one significant relationship. Patients with a body mass index above the mean had a 21% complication rate as compared with a 12% rate for those below the mean. Of note, there was no increase in complication rate in the context of multiple procedures.

CONCLUSIONS: This retrospective series is the largest to date involving outpatient reduction mammoplasty. Complication data derived from this series are comparable to previously published studies and thus support the safety and efficacy of outpatient reduction mammoplasty performed in an accredited facility. (*Aesthetic Surg J* 2008;28:171-179.)

From the Marina Plastic Surgery Associates and the Keck School of Medicine, University of Southern California, Los Angeles, California.

Beginning in the 1970s, a paradigm shift occurred in the United States involving outpatient surgery.¹ From 1979 to 1989, outpatient surgical procedures increased by 300%.^{2,3} As of 2005 an estimated 4 of 5

surgical procedures were performed in outpatient facilities.⁴ Multiple studies have demonstrated a savings between 25% to 50% in comparison to inpatient-based surgery without an increase in complication rates.^{1,5,6}

Plastic surgery has been at the forefront of outpatient-based surgery, particularly in conjunction with the boom in cosmetic surgery. According to data from the American Society for Aesthetic Plastic Surgery, nearly 11.5 million surgical and nonsurgical cosmetic procedures were performed in the United States in 2006.⁷ The majority of these procedures were performed on an outpatient basis.

Reduction mammoplasty is the fifth most commonly performed procedure by plastic surgeons, with 145,822 being performed in 2006 alone.⁷ Historically, reduction mammoplasty has been relegated to an inpatient setting, with an obligatory hospital stay of 1 to 2 days. In the last 10 years, reduction mammoplasties have been increasingly performed on an outpatient basis. Despite this fact, there is a paucity of studies in the literature documenting outcomes in outpatient reduction surgery. Since 1996, a total of 4 articles have been published addressing this subject.^{1,6,8,9} Of these articles, the largest series involved 286 patients.⁸ The purpose of this study was to examine clinical outcomes in a large series of reduction mammoplasties performed in an outpatient setting to document safety and efficacy.

METHODS

A retrospective chart review was conducted on 884 reduction mammoplasties in 444 patients performed by the senior author (W.G.S.) over an 11-year period (1995–2006). All cases were performed at a single outpatient surgery facility certified by the American Association for Accreditation of Ambulatory Surgery Facilities. Demographic information collected included age, weight, height, body mass index (Quetelet's index [height/weight]), bra size, sternal notch to nipple and sternal notch to inframammary fold measurements, chest circumference, medical conditions, hemoglobin level, American Society of Anesthesia physical status, and smoking status. Surgical data collected included operative time, resection weight, surgical technique used, ancillary procedures performed, duration of drain placement, and surgical pathology. Complication data were stratified into minor and major complications. Potential minor complications included seroma formation, hematoma, soft tissue infection, dog ears requiring revision, and small incisional breakdown or delayed healing of less than 2 cm. Potential major complications included large incisional breakdown or delayed healing of greater than 2 cm, nipple/areolar necrosis, need for blood transfusion, deep vein thrombosis, pulmonary embolus, myocardial infarction, and death. Data were compiled within an Excel spreadsheet (Microsoft Excel 2002; Microsoft Corp, Redmond, WA) and were subsequently converted to a SAS data set (SAS/STAT, version 11; SAS Institute Inc, Cary, NC). Statistical analysis

involved stratification of patient variables into two groups, one above and one below the mean, followed by χ^2 testing. Specific variables examined included age, body mass index (BMI), sternal notch to nipple distance, medical comorbidities, smoking status, duration of procedure, the addition of multiple procedures, and weight of resected tissue.

OPERATIVE TECHNIQUE

Preoperative markings (Wise pattern, "inverted T") were made with the patient in a standing position in the preoperative area. After being brought to the operating room, and before the induction of general anesthesia, sequential compression devices were placed on the lower extremities, and intravenous antibiotics were given. Foley catheters were not used. General anesthetic was then administered by a board-certified anesthesiologist in all cases. The breasts were then infiltrated with a tumescent solution containing normal saline solution 250 mL, 2% plain lidocaine 30 mL, and epinephrine 1 mg. Before being prepped and draped, pedicle deepithelialization was performed with a carbon dioxide laser, as described previously.¹⁰ After being prepped with povidone-iodine (Betadine) solution, formal dissection, creation of an inferior pedicle, and excision of tissue was performed sharply with a no. 10 scalpel blade. Hemostasis was achieved with electrocautery. Once completed, closure was achieved with a combination of interrupted 2-0, 3-0, and 4-0 intradermal Vicryl sutures followed by running 3-0 and 4-0 Monocryl sutures. Drains were used in all patients. Before 2002, Jackson Pratt drains were used. Because of pain with removal, a switch was made to Penrose drains. All patients ambulated within 1 hour of awakening from anesthesia. Patients were then either discharged home or to an after-care facility. Patients were then seen the following day in the office, where the dressings and drains were removed, Steri-strips (3M, St. Paul, MN) or porous tape were placed, and the patients were fitted with a soft, supportive bra.

RESULTS

Four hundred forty-four consecutive cases of laser-assisted, inferior pedicle, Wise pattern breast reductions were evaluated. Of these, 440 were bilateral reductions, whereas 4 cases were unilateral for either congenital asymmetry or breast reconstruction. Representative cases are illustrated in [Figures 1 to 4](#).

The mean patient age was 38 years (range, 16 to 73), and most patients were between the ages of 26 to 45 years ([Figure 5](#)). Mean BMI was 27 (range, 17 to 47), with most having a BMI of 30 or less ([Figure 6](#)). The reported preoperative brassiere cup sizes ranged from a 34 C to a 38 K, with a DD being the most common size ([Figure 7](#)). The distances measured before surgery from sternal notch to nipple averaged 29 cm (range, 22 to 54 cm). The most common measurement was 26 to 30 cm ([Figure 8](#)). Forty patients smoked (9%). Average clinical follow-up was 13 months.

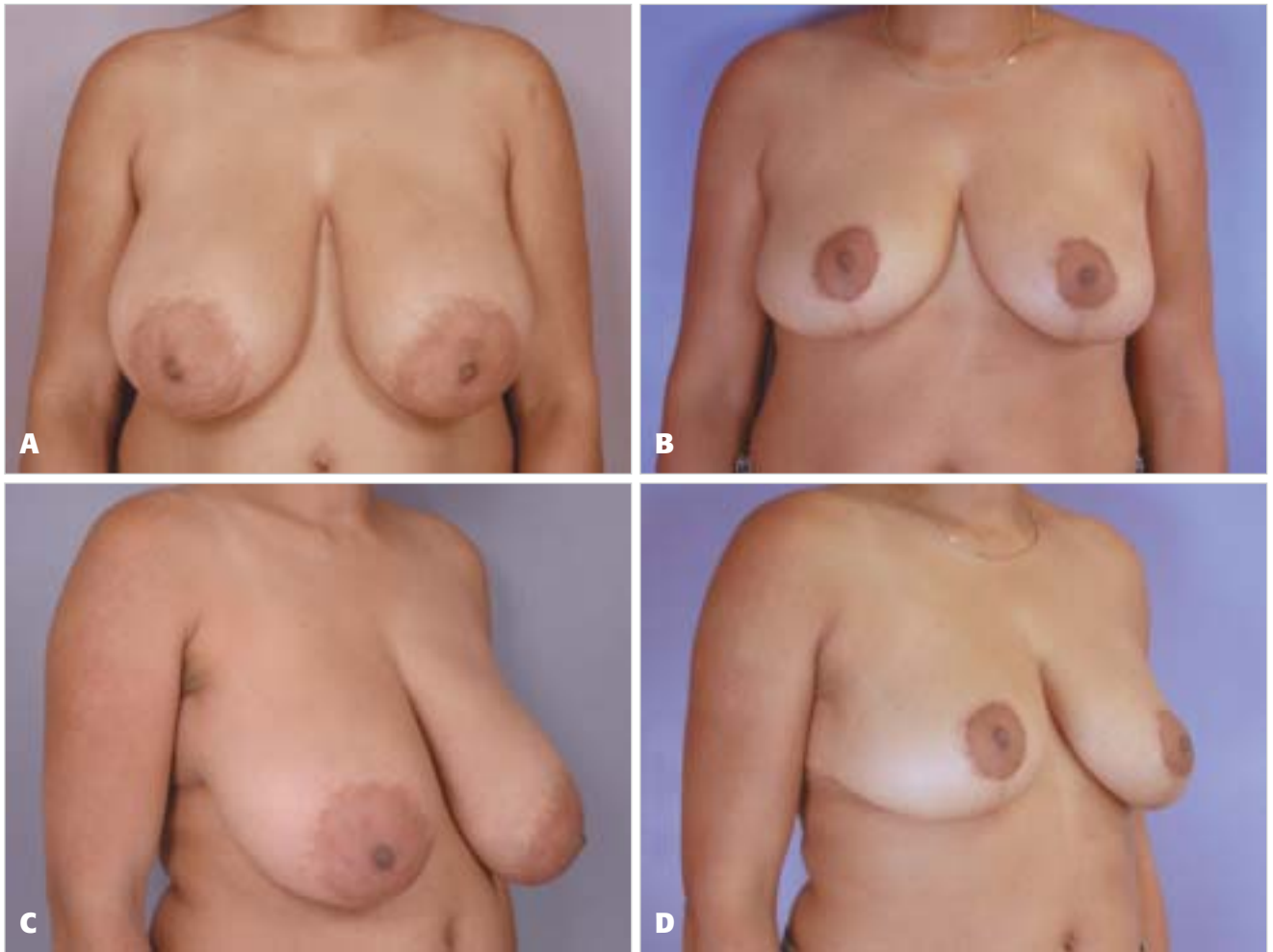


Figure 1. **A, C,** Preoperative views of a 45-year-old woman with 38 DDD breasts, a sternal notch-to-nipple distance measuring 34 cm on the right and 35 cm on the left, and a BMI of 27.8. **B, D,** Postoperative views 12 months after laser-assisted, inferior pedicle, Wise pattern reduction mammoplasty in which 835 g were removed from the right breast and 790 g from the left breast.

Mean total resection weight of breast tissue was 1228 g (range, 100 to 5295 g). The most common resection weight was between 1000 and 1500 g (Figure 9). Mean operative times for breast reductions, excluding cases that combined additional facial or trunk procedures, was 115 minutes, with a range of 50 minutes to 195 minutes (Figure 10). Eighty-four patients (19%) underwent multiple procedures, including abdominoplasty, lipoplasty, and facial procedures, and the mean operative time was 132 minutes (range, 75 to 345 minutes).

Of the 444 patients in this study, 70 minor complications occurred in 62 patients, representing a complication rate of 14%. Specific minor complications included 1 seroma (0.2%), 4 hematomas (0.9%), 8 soft tissue infections (1.8%), 2 of which required a short course of intravenous antibiotics, 1 patient with dog ears requiring a revision (0.2%), and 56 minor incisional wound breakdowns (12.6%, Figure 11). The incisional breakdowns, which represented the largest group of complications, were further subdivided into 44 minor T-zone wounds less than 2 cm, 3 nipple-areolar complex

(NAC) wounds, and 9 wounds of the vertical and horizontal incisions (Figure 12).

Three major complications (0.67%) were noted during this study. Two patients had development of partial nipple/areolar necrosis. The first involved a healthy 22-year-old female who was not obese or a smoker who had development of left partial NAC necrosis approximately 1 week after a 1515-g reduction. This was treated initially with wet to dry dressings, followed later by full-thickness grafting from the groin and subsequent tattooing. The second patient, who was an obese female smoker, had development of bilateral, partial nipple necrosis after a 3200-g reduction. She was treated with wet to dry dressings only and went on to heal with an acceptable aesthetic result. The third major complication involved an otherwise healthy woman who was diagnosed with a pulmonary embolus 10 days after an uncomplicated 808-g reduction. On her scheduled office visit, she was found to have anxiety, mild dyspnea, and mild tachycardia. She was promptly sent to the emergency department for evaluation, where the pulmonary embolus was diagnosed on

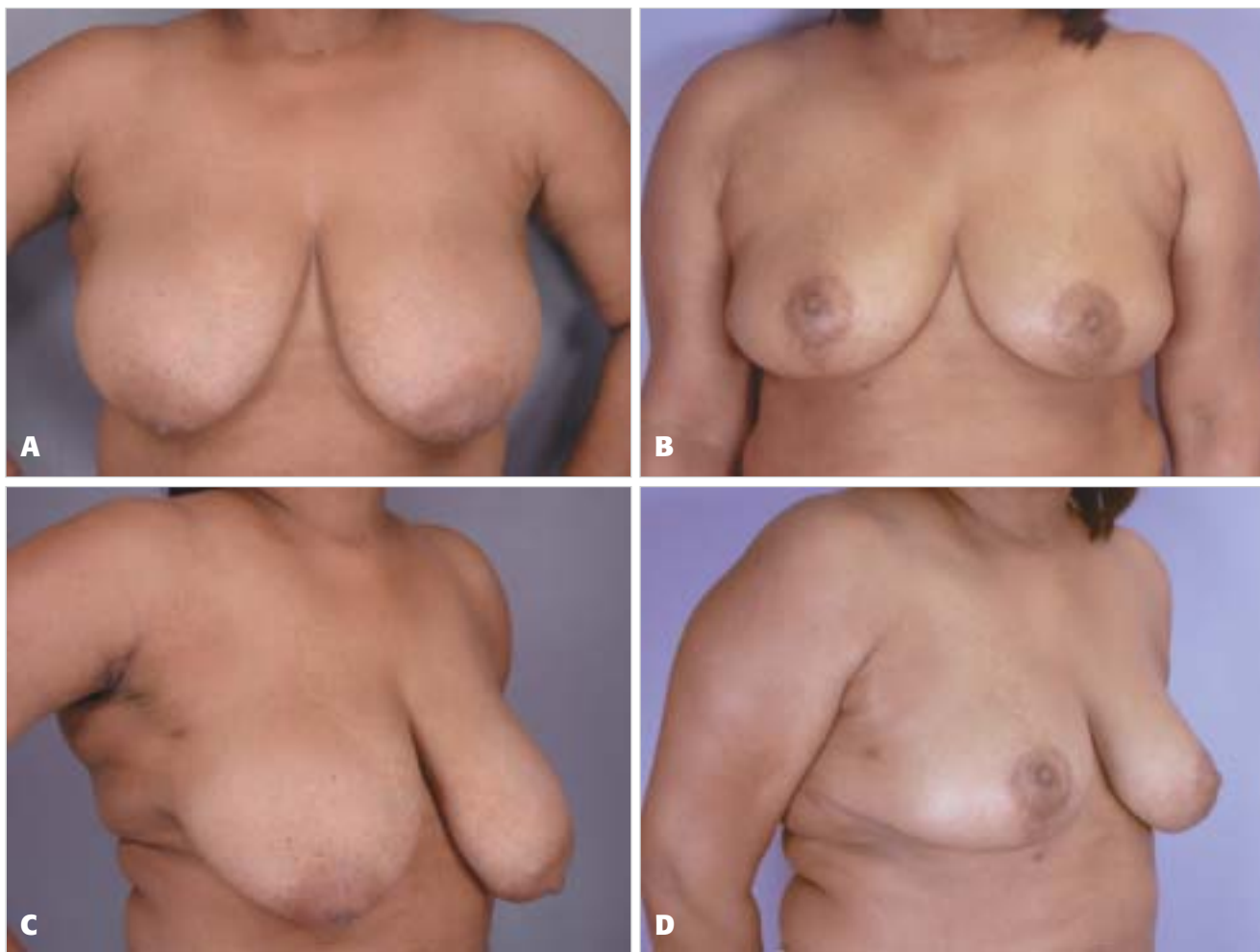


Figure 2. **A, C,** Preoperative views of a 52-year-old woman with 40 DD breasts, a sternal notch-to-nipple distance measuring 32 cm on the right and 33 cm on the left, and a BMI of 32.9. **B, D,** Postoperative views 9 months after laser-assisted, inferior pedicle, Wise pattern reduction mammoplasty in which 590 g were removed from the right breast and 665 g from the left breast.

computed tomography scanning, and she was given anti-coagulants. Of note, her recovery was uneventful, and the workup result for an occult coagulopathy was negative.

Statistical analysis of the complication data revealed one significant relationship. Patients with a BMI above the mean had a 21% complication rate as compared with a 12% rate for those below the mean. The vast majority of these complications were wound related. There was no statistically significant relationship between complications and age, resection weight of breast tissue, sternal to nipple distance, operative duration, multiple procedures, and smoking.

DISCUSSION

Breast reduction surgery is both safe and effective, a fact born out by multiple retrospective and prospective studies.¹¹⁻¹⁶ The average complication rate derived from the literature is 23%, and the most common complications include seroma, hematoma, delayed healing, infection, nipple-areola necrosis, fat necrosis, altered nipple sensation, and poor scarring.^{12,16-20} Until recent-

ly, breast reduction surgery has been conducted in an inpatient setting. Because of the ever-increasing emphasis on cost containment in health care, more surgeons are performing these procedures in an outpatient setting. Unfortunately, relatively few outcome-based studies exist in the literature focusing on outpatient reduction surgery.

Buenaventura et al⁸ wrote a comparative, retrospective review of 338 reduction mammoplasties, 286 of which were performed as outpatients. A significant difference existed between inpatient and outpatient groups with regard to mean age (42.4 vs 34.3, respectively) and resection weight (1895.6 g vs 1486.1 g).⁸ However, no significant differences existed in complication rates. Another retrospective study comparing outcomes in inpatient and outpatient reduction surgery was performed by Short et al.¹ Three hundred thirty-one reductions were examined, with 161 outpatients and 170 inpatients. A significant difference existed between the 2 groups with regard to body weight and complication rates.¹ The inpatient group was heavier and more likely

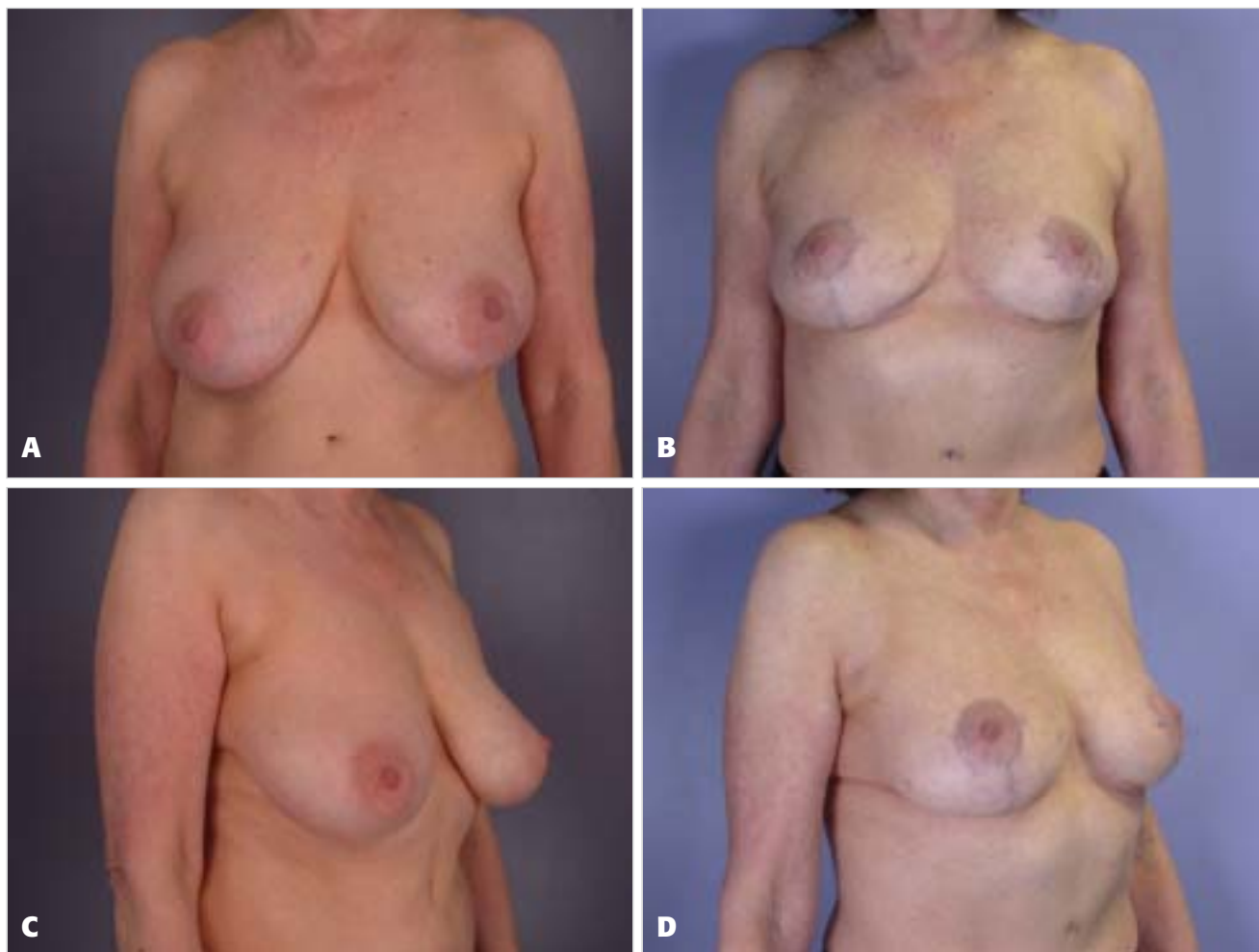


Figure 3. **A, C,** Preoperative views of a 71-year-old woman with 36 DD breasts, a sternal notch-to-nipple distance measuring 28 cm on the right and 27 cm on the left, and a BMI of 21.8. **B, D,** Postoperative views 13 months after laser-assisted, inferior pedicle, Wise pattern reduction mammoplasty in which 320 g were removed from the right breast and 290 g from the left breast.

to experience a complication. In their study, the primary complication difference involved poor wound healing.

In this study, the overall complication rate of 14% compares favorably with previous breast reduction literature, most of which involved surgery performed on an inpatient basis. Furthermore, the rate of delayed healing, the most common complication, was less than average, including the 21.6% incidence noted in the recent multicenter BRAVO study.¹⁶ In our statistical analysis, the only variable associated with complications with statistical significance was BMI. Twenty-one percent of patients with an above-average BMI had development of complications versus only 12% for those with a below-average BMI. This finding is not a new one because as several previous studies have noted this relationship.^{16,21,22} Unfortunately, variability exists within the breast reduction literature because of differing measures of obesity. The use of BMI is a more recent and accurate measurement tool in this regard but has not been^{22,23} applied until recently.²¹ In previous studies, including the multicenter BRAVO study, BMI is linked most commonly to

poor wound healing, a finding mirrored in this study.¹⁶ Additional variables examined, including smoking status, sternal notch to nipple measurements, and resection weight, failed to demonstrate statistical significance.

Regarding major complications, the incidence of NAC necrosis in this study was 0.45%, considerably lower than the published average. In the BRAVO study, the incidence of NAC necrosis was 3.6%.¹⁶ The incidence of pulmonary embolus in the reduction literature ranges from 0.4% to 0.8%, and the incidence in this study was 0.22%.²⁴ Our single case of pulmonary embolus involved an otherwise healthy 24-year-old woman who was not obese, did not smoke, and underwent an uneventful reduction without any additional procedures. Her embolic event did not manifest until 10 days after surgery during a routine office follow-up. The subsequent workup result for an occult coagulopathy was negative, and the patient was treated with a standard anticoagulation protocol.

Safe and effective performance of outpatient surgery is based on several elements. First, use of an accredited

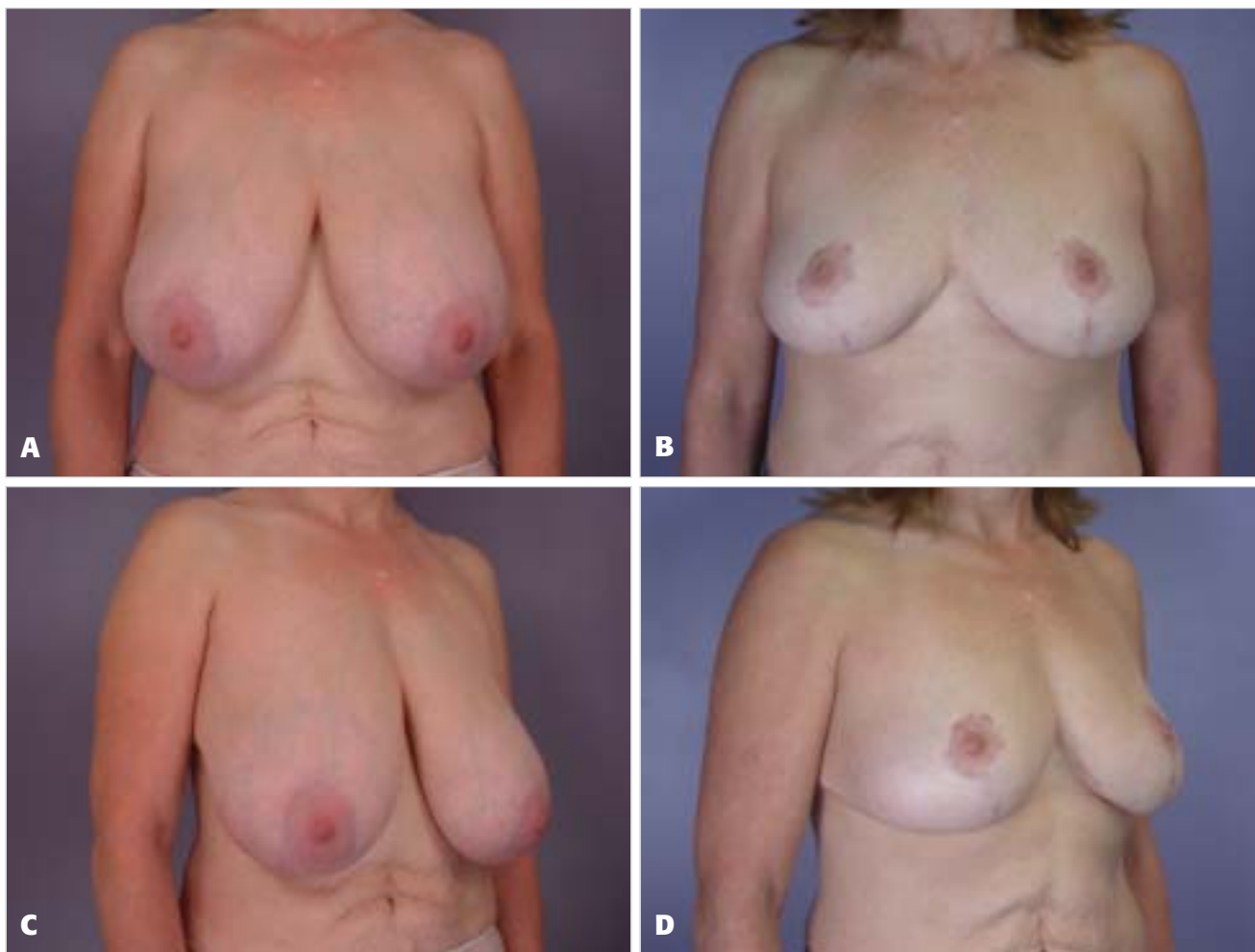


Figure 4. **A, C,** Preoperative views of a 50-year-old woman with 38 DD breasts, a sternal notch-to-nipple distance measuring 31 cm on the right and 31 cm on the left, and a BMI of 24. **B, D,** Postoperative views 58 months after laser-assisted, inferior pedicle, Wise pattern reduction mammoplasty in which 720 g were removed from the right breast and 640 g from the left breast.

outpatient ambulatory surgery center is, in our opinion, and in the opinion of the American Society of Plastic Surgeons and the American Society for Aesthetic Plastic Surgery as of 2002, mandatory.²⁴ As the study performed by Byrd et al⁴ of 5316 consecutive cases performed in an accredited outpatient facility clearly demonstrated, surgery can be safely performed with minimal complications in an outpatient setting. For us, this protocol includes use of board-certified anesthesiologists for all cases. In addition, we believe it is desirable to avoid long procedure times. Average procedure time for reductions alone was 108 minutes, and no combined procedure cases lasted more than 4 hours. Several recent studies have demonstrated that combined procedures can be performed safely on an outpatient basis.^{25,26} In a recent article by Stevens et al²⁶ examining 151 cases of abdominoplasty combined with breast surgery, no association existed between combined surgery and complication rate in comparison to breast cases alone. Of note, the average surgical times for combined cases in that study was less than 3 hours (mean 170 minutes).²⁶

Another important element is aftercare. Patients require responsible caregivers after surgery. Whether they are at home or in an aftercare facility, patients should not spend the first few postoperative days alone. Venous thromboembolic precautions are taken not only before and during surgery, but also after surgery with an aggressive ambulation regimen that begins the first night after surgery. An early ambulation regimen has not always been the standard of care, as evidenced by the 1977 survey by Grazer and Goldwyn²⁷ involving 10,490 abdominoplasties. Only 35% of patients were ambulatory within 24 hours of surgery, and 10% of patients did not walk until more than 4 days after surgery.²⁸ The incidence of deep vein thrombosis and pulmonary embolus in that study was 1.1% and 0.8%, respectively, and we believe that this rate may be lowered further with early ambulation.²⁷ Finally, early and frequent office visits enhance patient safety. In our practice, patients are seen on postoperative day number one and again at 7 to 10 days. The case of pulmonary embolus was recognized during the second postoperative visit at 10 days after surgery.

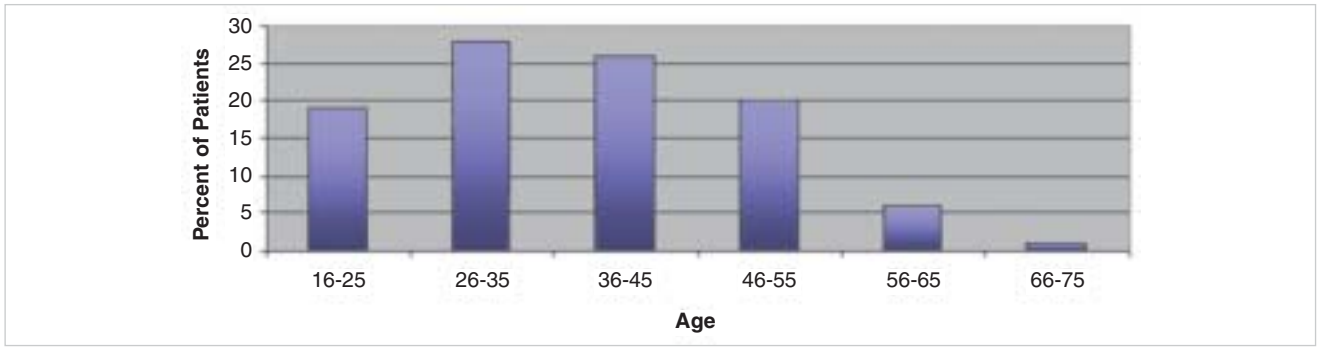


Figure 5. Patient age.

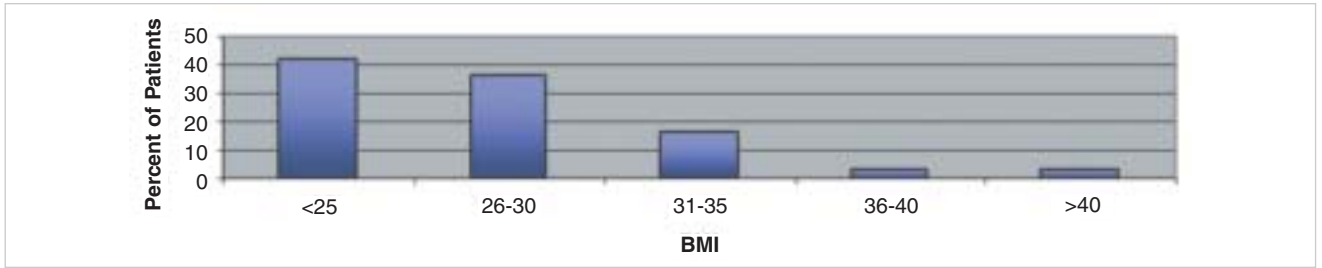


Figure 6. BMI distribution.

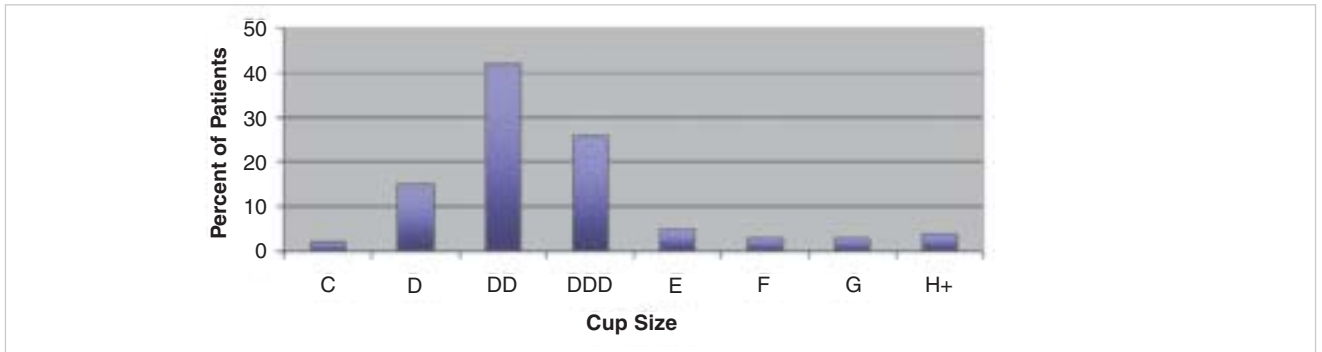


Figure 7. Cup size distribution.

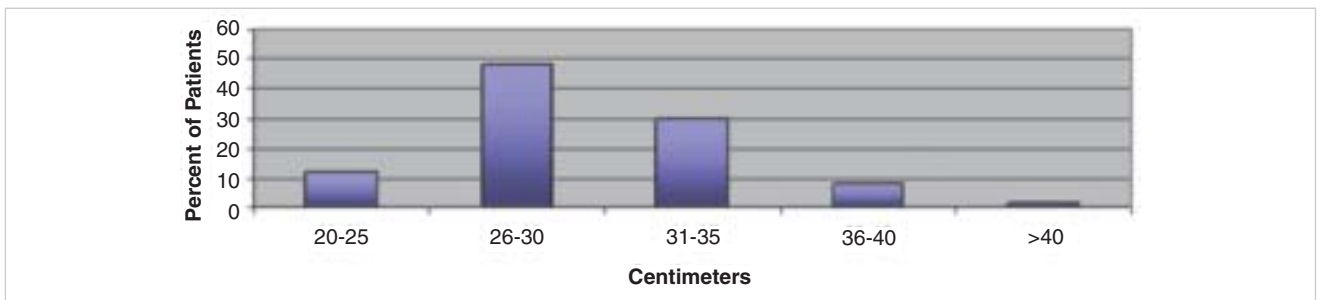


Figure 8. Sternal notch-to-nipple distance.

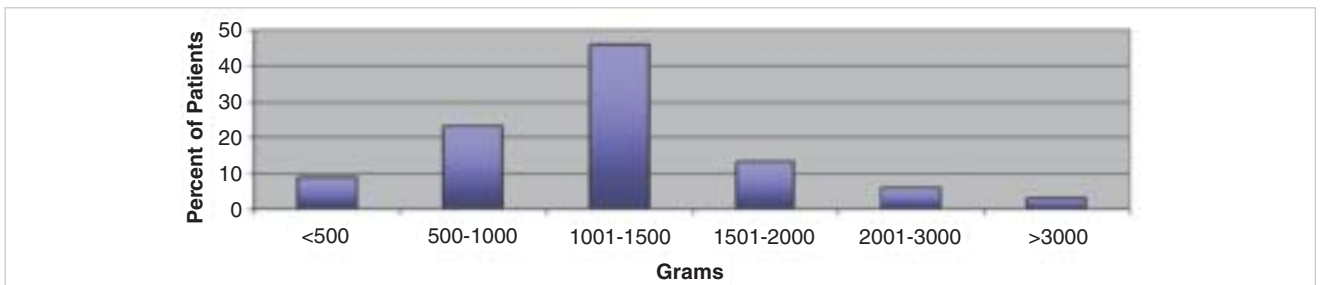


Figure 9. Total grams removed.

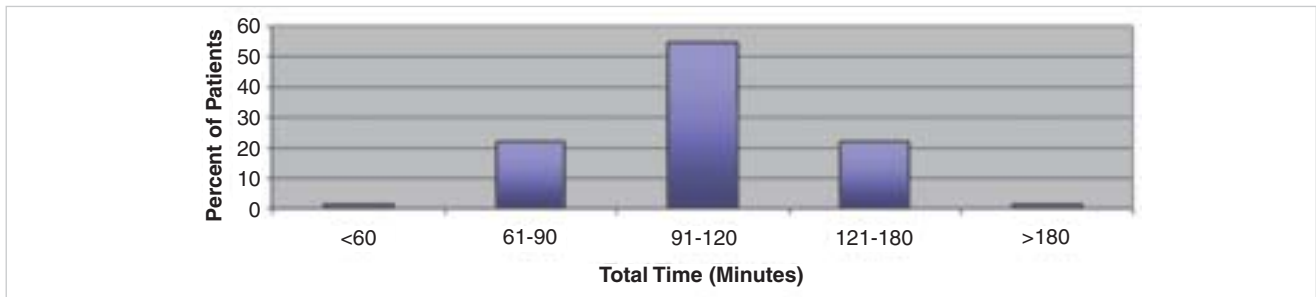


Figure 10. Duration of surgery.

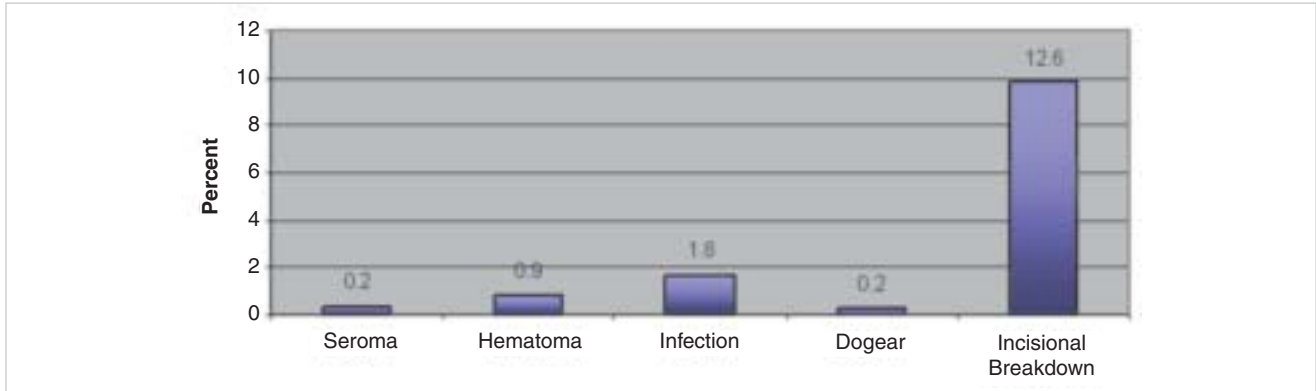


Figure 11. Percent occurrence of complications.

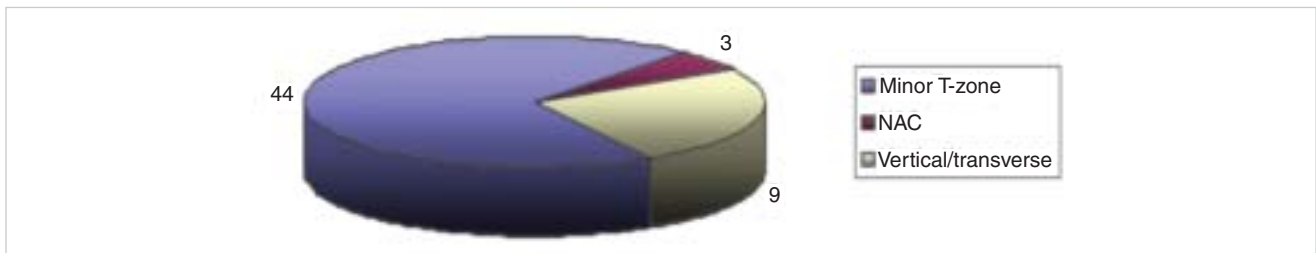


Figure 12. Incisional wound complications.

CONCLUSION

This large retrospective study of 884 consecutive reduction mammoplasties performed on 444 patients in an outpatient setting clearly demonstrates that breast reduction surgery may be performed safely and effectively at an accredited outpatient surgery facility. ■

DISCLOSURES

The authors have no financial interest in and receive no compensation from manufacturers of products mentioned in this article.

REFERENCES

- Short KK, Ringler SL, Bengtson BP, Hunstad JP, Henry E. Reduction mammoplasty: a safe and effective outpatient procedure. *Aesthetic Plast Surg* 1996;20:513-518.
- Detmer DE, Buchanan-Davidson DJ. Ambulatory surgery. *Surg Clin North Am* 1982;62:685-704.
- Detmer DE, Gelijns AC. Ambulatory surgery: a more cost-effective treatment strategy? *Arch Surg* 1994;129:123-127.
- Byrd HS, Barton FE, Orenstein HH, Rohrich RJ, Burns AJ, Hobar PC, et al. Safety and efficacy in an accredited outpatient plastic surgery facility: a review of 5316 consecutive cases. *Plast Reconstr Surg* 2003;112:636-641.

- Dasid J, Detmer DE. The ambulatory surgical unit. *Ann Surg* 1972;175:856.
- Davies BW, Lewis RD, Pennington GA. Reduction mammoplasty: a comparison of outpatient and inpatient procedures. *Aesthetic Plast Surg* 1996;20:77-80.
- American Society for Aesthetic Plastic Surgery. 2006 Cosmetic Surgery National Data Bank Statistics. News release. American Society for Aesthetic Plastic Surgery. 2006.
- Buenaventura S, Severinac R, Mullis W, Beasley M, Jacobs W, Wood D. Outpatient reduction mammoplasty: a review of 338 consecutive cases. *Ann Plast Surg* 1996;36:162-166.
- Scott GR, Carson CL, Borah GL. Maximizing outcomes in breast reduction surgery: a review of 518 consecutive patients. *Plast Reconstr Surg* 2005;116:1633-1639; discussion 1640-1641.
- Stevens WG, Cohen R, Schantz SA, Stoker DA, Vath SD, Hirsch EM, et al. Laser-assisted breast reduction: a safe and effective alternative. A study of 367 patients. *Aesthetic Surg J* 2006;26:432-439.
- Pers M, Nielsen IM, Gerner N. Results following reduction mammoplasty as evaluated by the patients. *Ann Plast Surg* 1986;17:449-455.
- Dabbah A, Lehman JA Jr, Parker MG, Tantri D, Wagner DS. Reduction mammoplasty: an outcome analysis. *Ann Plast Surg* 1995;35:337-341.

13. Gonzalez F, Walton RL, Shafer B, Matory WE Jr, Borah GL. Reduction mammoplasty improves symptoms of macromastia. *Plast Reconstr Surg* 1993;91:1270–1276.
14. Davis GM, Ringler SL, Short K, Sherrick D, Bengtson BP. Reduction mammoplasty: long-term efficacy, morbidity, and patient satisfaction. *Plast Reconstr Surg* 1995;96:1106–1110.
15. Chao JD, Memmel HC, Redding JF, Egan L, Odom LC, Casas LA. Reduction mammoplasty is a functional operation, improving quality of life in symptomatic women: a prospective, single-center breast reduction outcome study. *Plast Reconstr Surg* 2002;110:1644–1652.
16. Cunningham BL, Gear AJ, Kerrigan CL, Collins ED. Analysis of breast reduction complications derived from the BRAVO study. *Plast Reconstr Surg* 2005;115:1597–1604.
17. Strombeck JO. Reduction mammoplasty. *Surg Clin North Am* 1971;51:453–469.
18. Menke H, Eisenmann-Klein M, Olbrisch RR, Exner K. Continuous quality management of breast hypertrophy by the German Association of Plastic Surgeons: a preliminary report. *Ann Plast Surg* 2001;46:594–598.
19. Zubowski R, Zins JE, Foray-Kaplon A, Yetman RJ, Lucas AR, Papay FA, et al. Relationship of obesity and specimen weight to complications in reduction mammoplasty. *Plast Reconstr Surg* 2000;106:998–1003.
20. Mandrekas AD, Zambacos GJ, Anastasopoulos A, Hapsas DA. Reduction mammoplasty with the inferior pedicle technique: early and late complications in 371 patients. *Br J Plast Surg* 1996;49:442–446.
21. Lahiri A, Duff CG, Brown TL, Griffiths RW. Anthropometric measurements and their value in predicting complications following reduction mammoplasty and abdominoplasty. *Ann Plast Surg* 2006;56:248–250.
22. Gamboa-Bobadilla GM, Killingsworth C. Large-volume reduction mammoplasty: the effect of body mass index on postoperative complications. *Ann Plast Surg* 2007;58:246–249.
23. Bolger WE, Seyfer AE, Jackson SM. Reduction mammoplasty using the inferior glandular “pyramid” pedicle: experiences with 300 patients. *Plast Reconstr Surg* 1987;80:75–84.
24. ASPS, *Policy statement on accreditation of office facilities*. 2003, American Society of Plastic Surgeons web site: [Paul, add ASAPS. <http://www.surgery.org/press/news-release.php?iid=142§ion=news-credentials>] <http://www.plasticsurgery.org/psf/psfhome/govern/officepol.cfm>.
25. Stevens WG, Vath SD, Stoker DA. “Extreme” cosmetic surgery: a retrospective study of morbidity in patients undergoing combined procedures. *Aesthetic Surg J* 2004;24:314–318.
26. Stevens WG, Cohen R, Vath SD, Stoker DA, Hirsch EM. Is it safe to combine abdominoplasty with elective breast surgery? A review of 151 consecutive cases. *Plast Reconstr Surg* 2006;118:207–212.
27. Grazer FM, Goldwyn RM. Abdominoplasty assessed by survey, with emphasis on complications. *Plast Reconstr Surg* 1977;59:513–517.

Accepted for publication June 7, 2007.

Reprint requests: W. Grant Stevens, MD, 4644 Lincoln Blvd, Suite 552, Marina del Ray, CA 90292.

Copyright © 2008 by The American Society for Aesthetic Plastic Surgery, Inc. 1090-820X/\$34.00

doi:10.1016.j.asj.2008.01.001
